ENVIRONMENTAL RESEARCH 29, 238–244 (1982)

Pleural Mesotheliomas in Sprague–Dawley Rats by Erionite: First Experimental Evidence

CESARE MALTONI, FRANCO MINARDI, AND LEONILDO MORISI

Institute of Oncology, Bologna, Italy

Received March 9, 1982

Erionite and crocidolite fibers were tested for carcinogenicity by intrapleural and intraperitoneal injection (*una tantum*) in 40 Sprague–Dawley rats per route for each fiber type. Pleural mesotheliomas were found in nine of ten animals that died within a year after intrapleural injection with erionite fibers. No pleural tumors were found among the animals treated at the same time and in the same way with crocidolite. Intraperitoneal injection of erionite did not produce mesotheliomas of the peritoneum, while a high incidence of these tumors was found among the animals treated by intraperitoneal injection of crocidolite. The studies are still in progress.

A large, integrated project of long-term bioassays of durable fibrous materials is now being carried out at the Institute of Oncology in Bologna.

Among the materials being studied are asbestos of different types and origins; various types of natural (sedimentary and hydrothermal) zeolites, including erionite; several synthetic zeolites; and other organic, natural and man-made solid compounds, such as silica, alumina, talc, caolin, glass fibers, propylene fibers, etc.

The purpose of the project is not only to identify any compounds that may be carcinogenic, but also to provide a relative risk assessment of those proving to be positive.

The compounds are being tested by intraperitoneal and, in many instances, also by intrapleural and subcutaneous injection on groups of 40 (20 male and 20 female) 8-week-old, Sprague–Dawley rats. Each compound is injected *una tantum* at a standard dose of 25 mg in 1 ml of H_2O. Groups of 20 males and 20 females, injected intraperitoneally, intrapleurally, and subcutaneously with 1 ml of H_2O, serve as controls.

The animals are allowed to live until spontaneous death. They are examined and weighed every 2 weeks during the first year of experiment, and thereafter every 8 weeks. All detectable gross pathological changes are recorded during the examination. The animals, when moribund, are isolated to prevent cannibalism.

A complete necropsy is performed on each animal. Histological examination is made on subcutaneous tissues at the site of injection and on the thymus, lungs, liver, kidneys, adrenals, spleen, mesentery, gonads, uterus, and any other organ with pathological changes.

Sedimentary erionite (kindly provided by Professor G. Gottardi, Institute of Minerology, University of Modena, Italy) was tested by all three routes: i.e., by intraperitoneal, intrapleural, and subcutaneous injections. The studies with this

0013-9351/82/050238-07$02.00/0
Copyright © 1982 by Academic Press, Inc.
All rights of reproduction in any form reserved.

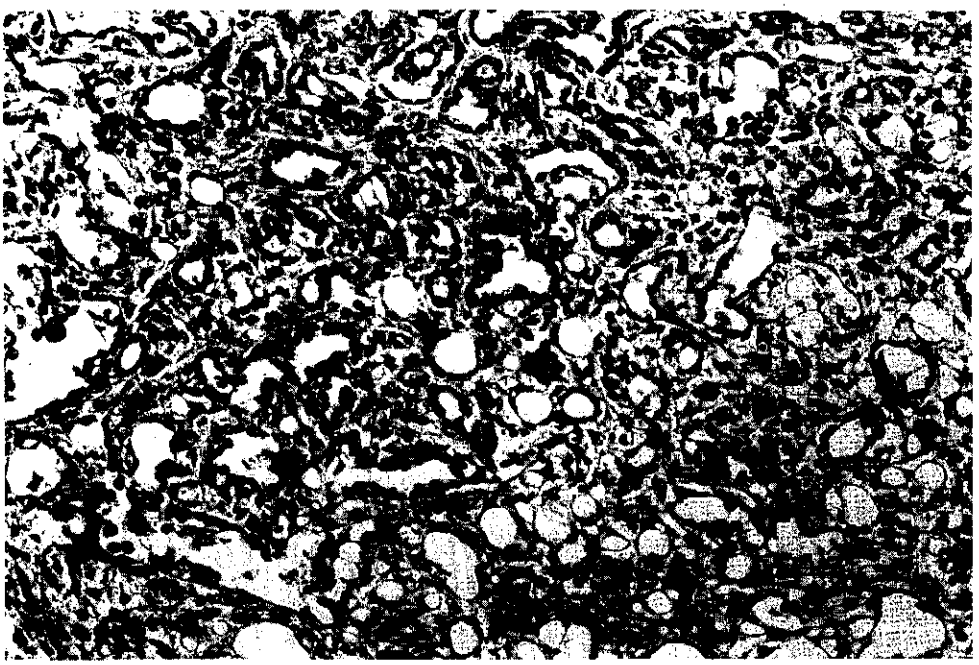

FIG. 1. Pleural mesothelioma from erionite: tubular pattern. H.-E., ×190.



FIG. 2. Pleural mesothelioma from erionite: tubular pattern. Hyaluronic acid is present in the lumina of several tubuli. H.-E., ×190.

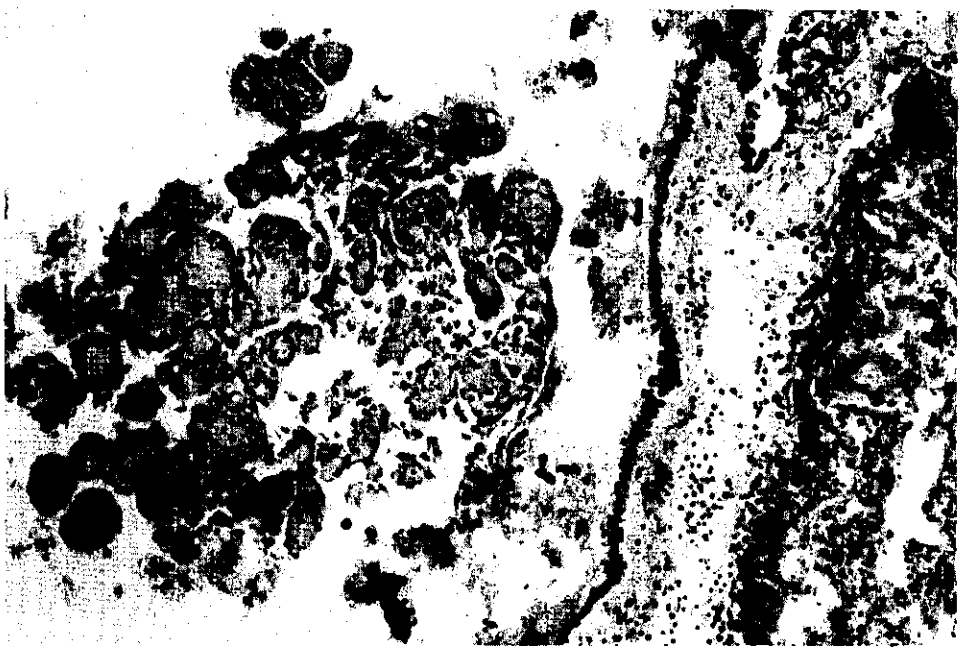

FIG. 3. Pleural mesothelioma from erionite: papillary pattern. H.-E., ×122.

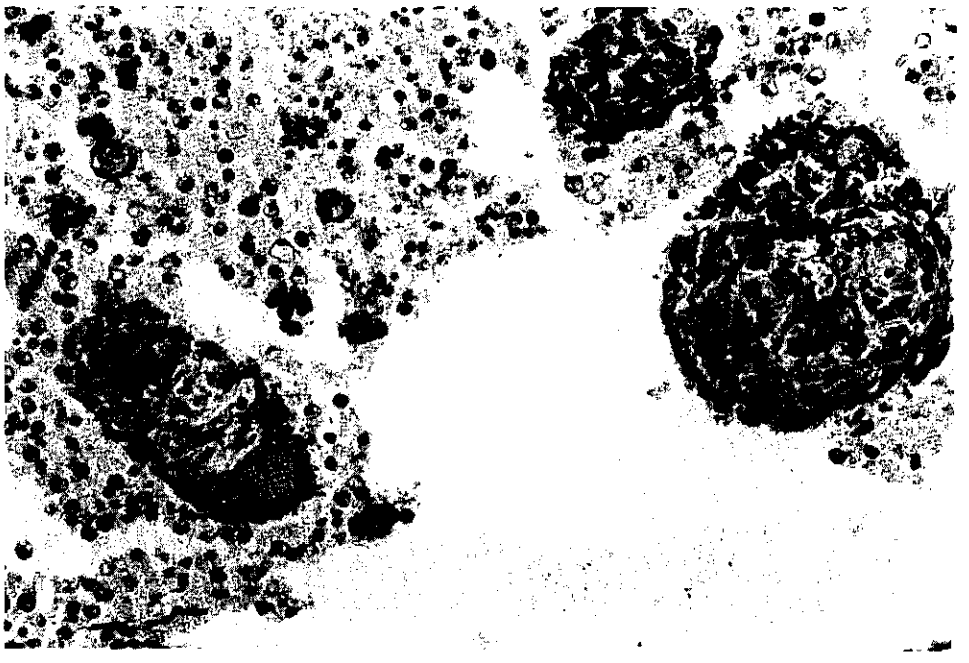

FIG. 4. Groups of mesothelioma cells, with papillary arrangement, in pleural effusion. H.-E., ×190.

ıttern. H.-E., ×122.



FIG. 5. Pleural mesothelioma from erionite: epithelium-like pattern. H.-E., ×190.

in pleural effusion. H.-E., ×190.

FIG. 6. Pleural mesothelioma from erionite: spindle-cellular pattern. H.-E., ×190.

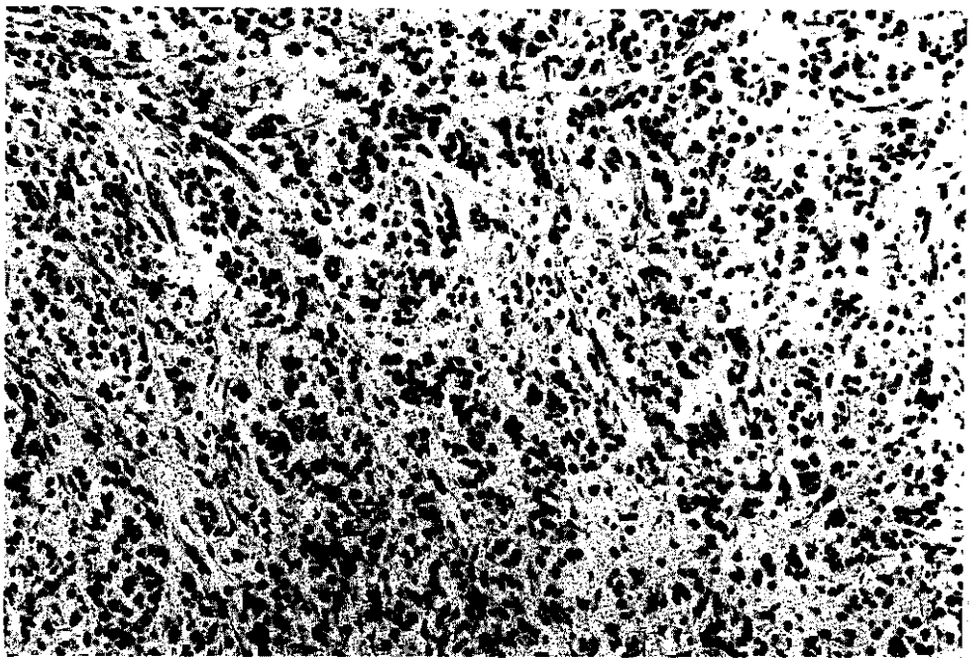

FIG. 7. Pleural mesothelioma from erionite: bimodal pattern (epithelium-like and spindle-cellular). H.-E., ×190.

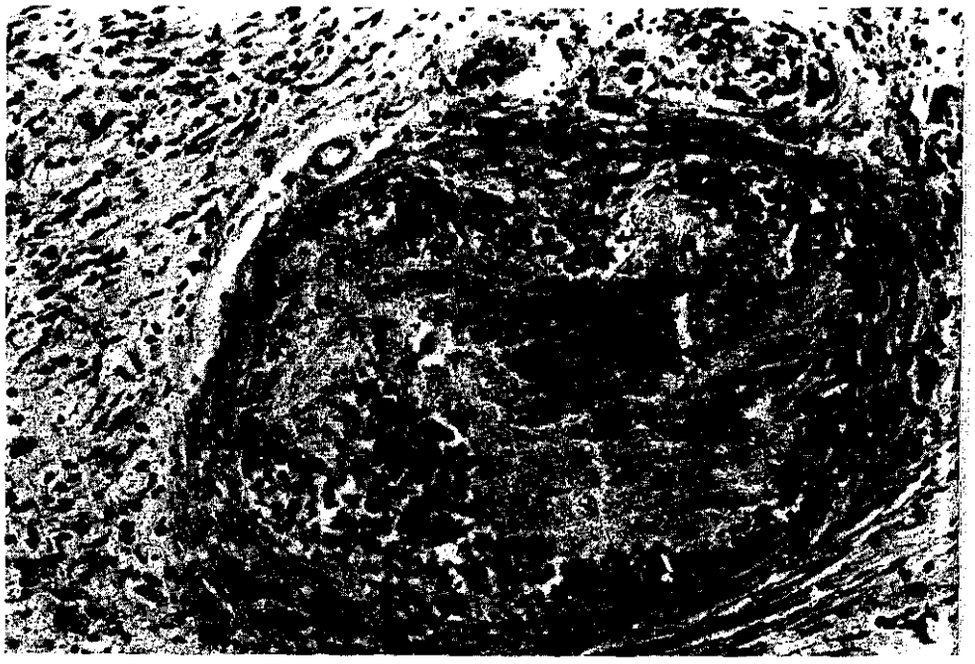

FIG. 8. Deposit of erionite within a pleural mesothelioma. H.-E., ×190.

thelium-like and spindle-cellular).

elioma. H.-E., ×190.

TABLE 1

PLEURAL MESOTHELIOMAS IN SPRAGUE–DAWLEY RATS FOLLOWING LOCAL INJECTION OF ERIONITE (RESULTS AFTER 53 WEEKS)

Compound	Route of administration	Animals			Tumors at the site of injection	
		Sex	No. at start	No. of survivors	Pleural mesotheliomas	Peritoneal mesotheliomas
Erionite	Pleural	M	20	13	6[a]	0
		F	20	17	3[b]	0
		M + F	40	30	9	0
	Peritoneal	M	20	18	0	0
		F	20	20	0	0
		M + F	40	38	0	0
Crocidolite	Pleural	M	20	19	0	0
		F	20	18	0	0
		M + F	40	37	0	0
	Peritoneal	M	20	11	0	9
		F	20	17	0	3
		M + F	40	28	0	12
None (H_2O)	Pleural	M	20	19	0	0
		F	20	20	0	0
		M + F	40	39	0	0
		M	20	20	0	0
	Peritoneal	F	20	20	0	0
		M + F	40	40	0	0

[a] Latency time: 32, 47, 48, 52, and 53 (2) weeks.
[b] Latency time: 47, 52, and 53 weeks.

mineral were initiated 53 weeks ago. Results of the first year of the experiments by the intraperitoneal and intrapleural routes are reported here.

Erionite has been suspected of contributing to, or being the single causative agent involved in, pleural mesotheliomas found in residents of Turkey (Baris *et al.*, 1979).

Among the 40 rats treated by intrapleural injection of erionite, 10 animals died within 53 weeks, 9 with pleural mesotheliomas.

Upon gross examination, the visceral, parietal, and diaphragmatic pleura appeared thickened and whitish. Moreover, several hard, whitish or yellowish nodules, from 2 to 10 mm in diameter, were found scattered at different sites of the serosal surface. Mediastinal nodes were swollen and lungs were atelectatic.

Microscopically, the mesotheliomas are polymorphous with several or all of the following characteristics: tubular, papillary, epithelial-like (solid), and spindle-cellular (Figs. 1–7). The tumors, with a spotty or continuous distribution, line the pulmonary and parietal pleura and the pericardium, invade the lungs and the thoracic costal muscles, and metastasize to mediastinal nodes. Deposites of erionite surrounded by granulomatous reaction are seen within the neoplastic tissue (Fig. 8).

The results of the bioassays of erionite are shown in Table 1, together with the

results of the bioassays of crocidolite (UICC sample) (positive controls) in the same animal system, performed within the same project, at the same time.

The spontaneous incidence of mesotheliomas in our breed of Sprague–Dawley rats is very low. Of 2381 untreated animals kept alive until spontaneous death and periodically inspected and histopathologically examined, only 1 pleural mesothelioma was found among 1202 females, and 1 pericardial and 3 peritoneal mesotheliomas among 1179 males.

In our experimental system, erionite appears at present to be a potent direct carcinogen for pleura, more effective than crocidolite.

Moreover, our results suggest a different degree of responsiveness of pleura and peritoneum to erionite and crocidolite.

Other natural zeolites tested concurrently, in the same way, have failed to show oncogenic effects at the site of injection after 53 weeks.

REFERENCES

Baris, Y. I., Artvinli, M., and Sahin, A. A. (1979). Environmental mesothelioma in Turkey. *In* "Health Hazards of Asbestos Exposure" (I. J. Selikoff and E. C. Hammond, Eds.), Annals of the New York Academy of Sciences, Vol. 330, pp. 423–432.